CLINICAL PRACTICE GUIDELINES

The American Society of Colon and Rectal Surgeons Clinical Practice Guidelines for the Management of Anal Fissures

Jennifer S. Davids, M.D.[1] • Alexander T. Hawkins, M.D., M.P.H.[2]
Anuradha R. Bhama, M.D.[3] • Adina E. Feinberg, M.D.C.M.[4]
Michael J. Grieco, M.D.[5] • Amy L. Lightner, M.D.[3] • Daniel L. Feingold, M.D.[6]
Ian M. Paquette, M.D.[7]

On behalf of the Clinical Practice Guidelines Committee of the American Society of Colon and Rectal Surgeons
1 Division of Colon and Rectal Surgery, University of Massachusetts, Worcester, Massachusetts
2 Division of General Surgery, Section of Colon and Rectal Surgery, Vanderbilt University Medical Center, Nashville, Tennessee
3 Department of Colorectal Surgery, Cleveland Clinic, Cleveland, Ohio
4 Division of General Surgery, Joseph Brant Hospital, Burlington, Ontario, Canada
5 Division of Colon and Rectal Surgery, New York University, New York, New York
6 Division of Colon and Rectal Surgery, Rutgers University, New Brunswick, New Jersey
7 Division of Colon and Rectal Surgery, University of Cincinnati, Cincinnati, Ohio

The American Society of Colon and Rectal Surgeons (ASCRS) is dedicated to ensuring high-quality patient care by advancing the science, prevention, and management of disorders and diseases of the colon, rectum, and anus. The Clinical Practice Guidelines Committee is composed of society members who are chosen because they have demonstrated expertise in the specialty of colon and rectal surgery. This committee was created to lead international efforts in defining quality care for conditions related to the colon, rectum, and anus and develop clinical practice guidelines based on the best available evidence. Although not proscriptive, these guidelines provide information based on which decisions can be made and do not dictate a specific form of treatment. These guidelines are intended for use by all practitioners, health care workers, and patients who desire information on the management of the conditions addressed by the topics covered in these guidelines. These guidelines should not be deemed inclusive of all proper methods of care nor exclusive of methods of care reasonably directed toward obtaining the same results. The ultimate judgment regarding the propriety of any specific procedure must be made by the physician considering all the circumstances presented by the individual patient.

STATEMENT OF THE PROBLEM

The term *anal fissure* refers to a linear tear within the anal canal that usually extends from the dentate line toward the anal verge. Although this benign anorectal condition is commonly encountered in practice, there is a paucity of population-level data describing its incidence.[1] Trauma and irritation to the anal canal, often precipitated by either constipation or diarrhea, can lead to development of an anal fissure. The primary symptom associated with anal fissures is anal pain, provoked by defecation, and may last for several hours after defecation. The pain is usually sharp, feels like a tearing sensation or "passing glass," and can be debilitating because of the intensity. Anorectal bleeding may also be present, typically bright red when wiping. Anal fissures are most commonly located in the posterior midline (73%) but can be found in the anterior midline in 13% of women and 8% of men, with 2.6% occurring both anteriorly and posteriorly simultaneously.[2] Lateral fissures or multiple fissures are considered to be an atypical presentation and require a more comprehensive evaluation because of the association with

CME

Earn Continuing Education (CME) credit online at cme.lww.com. This activity has been approved for AMA PRA Category 1 credit.

Funding/Support: None reported.

Financial Disclosure: None reported.

Correspondence: Ian M. Paquette, M.D., Division of Colon and Rectal Surgery, College of Medicine, University of Cincinnati, 2123 Auburn Ave #524, Cincinnati, OH 45219. E-mail: ian.m.paquette@gmail.com

Dis Colon Rectum 2022; 66: 190–199
DOI: 10.1097/DCR.0000000000002664
© The ASCRS 2022

Copyright © The American Society of Colon & Rectal Surgeons, Inc. Unauthorized reproduction of this article is prohibited.

HIV infection, Crohn's disease, syphilis, tuberculosis, and hematologic malignancies.

Acute fissures, defined as symptoms present for <6 weeks,[3,4] will appear as a longitudinal tear. Fissures of a longer duration will often manifest 1 or more stigmata of chronicity, including a hypertrophied anal papilla at the proximal aspect of the fissure, a sentinel tag at the distal aspect of the fissure, and/or exposed internal anal sphincter muscle within the base of the fissure. The pathogenesis of chronic fissures arises from underlying hypertonicity of the internal anal sphincter, leading to local ischemia and impaired wound healing.[5] Most acute anal fissures are treated conservatively as recommended in the following section. The remainder of the practice guideline concerns patients with chronic anal fissure who present to a surgical clinic.

MATERIALS AND METHODS

These guidelines were built upon the previous ASCRS "Clinical Practice Guideline for the Management of Anal Fissures," published in 2017.[6] In comparison to the 2017 guideline, this guideline updated the evidence grade level on 4 recommendations, whereas the literature review and supporting text was updated for all other recommendations (Table 1). An organized search of MEDLINE, PubMed, Embase, Scopus, Web of Science, and the Cochrane Database of Collected Reviews was performed from October 1, 2014, through March 20, 2022, with the assistance of a medical librarian. Retrieved publications were limited to the English language and adult patients.

The search strategies were based on the concepts "anal fissure" and "fissure-in-ano" as primary search terms. Searches were also performed on the basis of various treatments for anal fissures, including "anal fissure AND nitroglycerin," "anal fissure AND nitrates," "anal fissure AND diltiazem," "anal fissure AND nifedipine," "anal fissure AND fiber," "anal fissure AND botulinum," "anal fissure AND sphincterotomy," "anal fissure and fissurectomy," "anal fissure and hemorrhoidectomy," "anal fissure AND dilation," and "anal fissure AND flap." Directed searches of the embedded references from the primary articles were also performed in certain circumstances. The initial search generated 740 eligible studies, and after removing 201 duplicates, 539 studies were screened for initial inclusion, with an additional 84 studies identified through other sources. Abstracts were screened for relevance, leaving 324 studies that each underwent full-text review by 2 coauthors, with all conflicts resolved by a third coauthor. Following full-text review, 221 studies were excluded; 86 studies were included in the final article (Fig. 1).

Prospective, randomized controlled trials (RCTs) and meta-analyses were given preference, but in the absence of higher-level evidence, peer-reviewed observational studies and retrospective studies were included. The final grade of recommendation was performed using the Grades of Recommendation, Assessment, Development, and Evaluation system (Table 2).[7] When the agreement was incomplete regarding the evidence base or treatment guideline, consensus from the committee chair, vice chair, and 2 assigned reviewers determined the outcome. Members of the ASCRS Clinical Practice Guidelines Committee worked in joint production of these guidelines from inception to final publication. The entire Clinical Practice Guidelines Committee reviewed recommendations formulated by the subcommittee. Final recommendations were approved by the ASCRS Executive Council and peer-reviewed in *Diseases of the Colon and Rectum*. In general, each ASCRS Clinical Practice Guideline is updated every 5 years. No funding was received for preparing this guideline, and the authors have declared no competing interests related to this material. This guideline conforms to the Appraisal of Guidelines for Research and Evaluation checklist.

RECOMMENDATIONS

1. Nonoperative treatment of acute anal fissures is safe and should typically be first-line treatment. Grade of recommendation: strong recommendation based on moderate-quality evidence, 1B.

TABLE 1. What is new in the 2022 ASCRS anal fissure clinical practice guideline

2022 Updated recommendations
2. Anal fissures may be treated with topical nitrates, although headache symptoms may limit their efficacy. Grade of recommendation: strong recommendation based on moderate-quality evidence, 1B.
3. Compared with topical nitrates, the use of calcium channel blockers for chronic anal fissures has a similar efficacy, with a superior side-effect profile, and can be used as first-line treatment. Grade of recommendation: strong recommendation based on moderate-quality evidence, 1B.
4. Botulinum toxin has similar results compared with topical therapies as first-line therapy for chronic anal fissures and modest improvement in healing rates as second-line therapy following failed treatment with topical therapies. Grade of recommendation: strong recommendation based on moderate-quality evidence, 1B.
8. Lateral internal sphincterotomy tailored to the length of the fissure yields similar healing rates but decreased fecal incontinence rates compared with traditional lateral internal sphincterotomy extending to the dentate line. Grade of recommendation: strong recommendation based on high-quality evidence, 1A.

ASCRS = American Society of Colon and Rectal Surgeons.

Copyright © The American Society of Colon & Rectal Surgeons, Inc. Unauthorized reproduction of this article is prohibited.

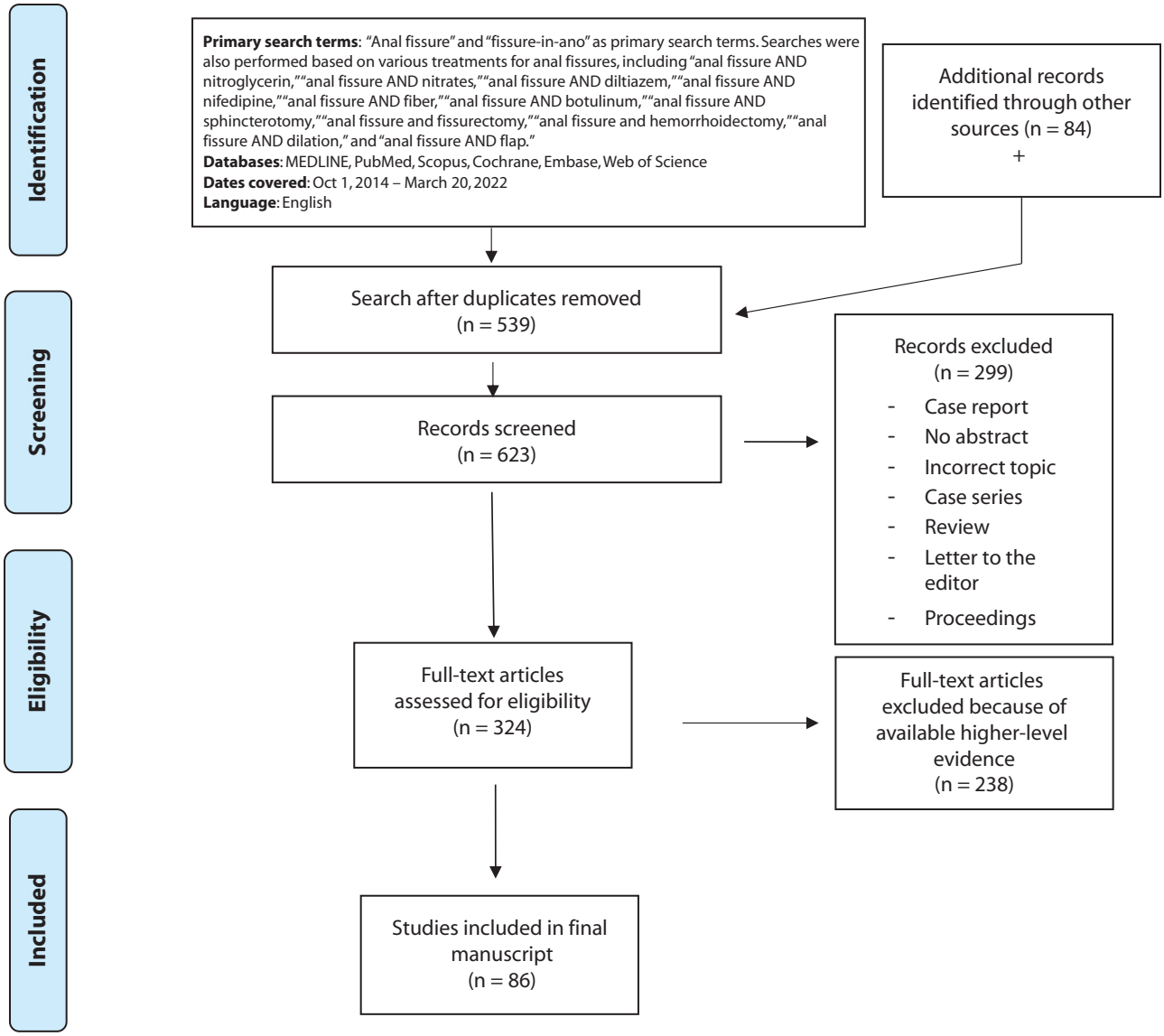

FIGURE 1. PRISMA literature search flow chart. PRISMA = Preferred Reporting Item for Systematic Reviews and Meta-Analysis.

Nearly half of all patients who have an acute anal fissure will resolve their symptoms with nonoperative measures such as sitz baths and the use of psyllium fiber or other bulking agents, with or without the addition of topical anesthetics or topical steroids.[1,2,8–11] These interventions are well tolerated with minimal to no side effects. In a prospective randomized trial of 103 patients, treatment with sitz baths and fiber supplementation was associated with a greater likelihood of pain relief compared to topical anesthetics or topical hydrocortisone (91% vs 60% vs 68%, respectively; $p < 0.05$).[8] In addition, in a double-blind placebo-controlled study of 75 patients with healed acute fissures, maintenance therapy with fiber was associated with lower rates of fissure recurrence compared with placebo (16% vs 60%; $p < 0.01$).[10] There are no data supporting one type of fiber in comparison with another. Healing rates of anal fissures with conservative treatment appear to decrease as duration of symptoms increases. This was demonstrated in a prospective study of 60 patients, which observed a 100% healing rate in patients with symptoms of <1-month duration, compared to only a 33.3% healing rate in patients with symptoms of >6-month duration.[12] The remainder of this clinical practice guideline discusses the management of chronic anal fissures. In general, chronic anal fissures require a tailored approach, as long-term consequences of surgical treatment, such as fecal incontinence (FI), may not manifest for several years.

2. Anal fissures may be treated with topical nitrates, although headache symptoms may limit their efficacy. Grade of recommendation: strong recommendation based on moderate-quality evidence, 1B.

Copyright © The American Society of Colon & Rectal Surgeons, Inc. Unauthorized reproduction of this article is prohibited.

TABLE 2. The GRADE system—grading recommendations

	Description	*Benefit vs risks and burdens*	*Methodologic quality of supporting evidence*	*Implications*
1A	Strong recommendation, high-quality evidence	Benefits clearly outweigh risks and burdens or vice versa	RCTs without important limitations or overwhelming evidence from observational studies	Strong recommendation; can apply to most patients in most circumstances without reservation
1B	Strong recommendation, moderate-quality evidence	Benefits clearly outweigh risks and burdens or vice versa	RCTs with important limitations (inconsistent results, methodologic flaws, indirect or imprecise) or exceptionally strong evidence from observational studies	Strong recommendation; can apply to most patients in most circumstances without reservation
1C	Strong recommendation, low or very low-quality evidence	Benefits clearly outweigh risks and burdens or vice versa	Observational studies or case series	Strong recommendation but may change when higher-quality evidence becomes available
2A	Weak recommendation, high-quality evidence	Benefits closely balanced with risks and burdens	RCTs without important limitations or overwhelming evidence from observational studies	Weak recommendation; best action may differ depending on circumstances or patients' or societal values
2B	Weak recommendation, moderate-quality evidence	Benefits closely balanced with risks and burdens	RCTs with important limitations (inconsistent results, methodologic flaws, indirect or imprecise) or exceptionally strong evidence from observational studies	Weak recommendation; best action may differ depending on circumstances or patients' or societal values
2C	Weak recommendation, low or very low-quality evidence	Uncertainty in the estimates of benefits, risks, and burdens; benefits, risks, and burdens may be closely balanced	Observational studies or case series	Very weak recommendation; other alternatives may be equally reasonable

GRADE = Grades of Recommendation, Assessment, Development, and Evaluation; RCT = randomized controlled trial.
Adapted from Guyatt et al.[7] Used with permission.

Topical nitroglycerin is associated with healing in approximately 50% of chronic anal fissures.[13] Based on a Cochrane meta-analysis of 18 randomized trials comparing topical nitrates to placebo, involving a total of 734 patients, the topical nitrate group was associated with a significantly decreased odds of fissure persistence or recurrence (OR 0.35; 95% CI, 0.19–0.65).[14] A multicenter double-blind placebo-controlled trial of 200 patients with anal fissure demonstrated that escalating concentrations of topical glyceryl trinitrate (GTN) was associated with increased rates of severe headache, with no improvement in fissure healing rates. Specifically, rates of severe headache were 2%, 6.5%, and 24% in the 0.1%, 0.2%, and 0.4% GTN groups, respectively. Higher doses were not associated with increased rates of healing, evidenced by similar healing rates of 47%, 40%, and 54% in the respective escalating treatment groups (p = 0.3).[15] Headache occurs in at least 30% of treated patients, is nearly ubiquitous in some reports,[16,17] and leads to cessation of therapy in up to 20% of patients.[18]

Although level-1 evidence supports the efficacy of topical nitrates, the side-effect profile should be considered as well. Additionally, there was significant heterogeneity in the clinical trials regarding the dose and delivery of the medication. Based on this, we changed the recommendation grade to 1B because the benefits must be closely balanced with the side effects.

3. Compared with topical nitrates, the use of calcium channel blockers for chronic anal fissures has similar efficacy, with a superior side-effect profile, and can be used as first-line treatment. Grade of recommendation: strong recommendation based on moderate-quality evidence, 1B.

A small prospective clinical trial of 45 patients compared anal fissure healing rates between groups randomly assigned to topical glyceryl trinitrate or diltiazem (DTZ) and found no difference in healing rates (54.9% vs 66.7%; p = 0.2) or in the percentage of patients who ultimately failed topical therapy (45% vs 33%; $p > 0.05$).[19] A 2013 systematic review of 7 randomized trials was conducted in 2013 with 238 patients treated with topical GTN versus topical DTZ. Although there was significant heterogeneity in the studies, DTZ was associated with a lower incidence of side effects (relative risk [RR] = 0.48 [0.27–0.86]) and lower incidence of headache (RR = 0.39 [0.24–0.66]) than GTN, with no difference in healing of chronic anal fissures (RR = 1.10 [0.90–1.34]).[20] A more recent 2020 meta-analysis of 8 RCTs demonstrated DTZ was better tolerated than glyceryl trinitrate with regard to headache occurrence (RR = 0.15 [0.07–0.34]).[21]

Studies evaluating the use of oral calcium channel blockers to treat anal fissures have conflicting results. One RCT demonstrated improved efficacy with topical

Copyright © The American Society of Colon & Rectal Surgeons, Inc. Unauthorized reproduction of this article is prohibited.

treatment over oral treatment (73.3% healing vs 49.5% healing; $p < 0.05$),[22] whereas another report found equal success.[23] Topical delivery is preferred, given the lower incidence of systemic effects associated with topical calcium channel blockers (4.3% vs 38.0%; $p < 0.0001$).[22,24]

Although there are several randomized clinical trials and meta-analyses evaluating this topic, the studies were heterogeneous and used different medications and different strengths; the available evidence supports a grade 1B recommendation.

4. Botulinum toxin has similar results compared with topical therapies as first-line therapy for chronic anal fissures and modest improvement in healing rates as second-line therapy following failed treatment with topical therapies. Grade of recommendation: strong recommendation based on moderate-quality evidence, 1B.

There is no consensus protocol for dosing of botulinum toxin or injection technique,[25] and therefore, there is heterogeneity between studies with regard to the dose injected, site(s) injected, and number of injections. A Cochrane review from 2012 found no clear trend between dose, preparation, or injection site of botulinum toxin and associated healing rates.[14] A meta-analysis of 1577 patients demonstrated no dose dependency with regard to healing rates, which ranged from 33% to 96%, or complications, including an overall 5% incidence of transient FI.[26] Another meta-analysis of 1158 patients from 18 clinical trials actually demonstrated greater efficacy with lower doses with the added benefits of lower rates of both FI and recurrence. Regression analysis, with increasing dosage, revealed that there was a small decrease in healing rates by 0.34% (95% CI, 0%–0.68%) and an increase in incontinence rate (RR = 1.02; 95% CI, 1.0002–1.049) and recurrence rate (RR = 1.04; 95% CI, 1.02–1.06).[27] Only 1 retrospective review addressed risk factors for nonhealing, demonstrating that predictors of success with botulinum toxin included female sex and lower BMI.[28]

Prospective studies suggest that in direct comparison with 0.2% to 1% topical nitroglycerin and 0.2% topical nifedipine, botulinum toxin (20–60 units) is associated with healing in 67% of patients, which is comparable to the 71% reported with topical therapies.[29,30] A double-blind randomized trial comparing topical 2% DTZ with 20 units of botulinum toxin (using placebo injections and topical preparations, respectively) demonstrated that both treatment arms were associated with a 43% healing rate after 3 months, and similar rates of patients reporting at least a 50% reduction in pain score (82% vs 78%; $p = 0.142$)).[31] A meta-analysis from 2008 concluded that botulinum toxin is as effective as nitroglycerin but that it may be associated with a lower incidence of adverse events.[32] A multicenter randomized study performed in 2014 suggested that botulinum toxin is more effective than topical nitroglycerin, with significantly improved rates of healing (67% vs 33%; $p = 0.01$) and with lower recurrence rates at 1 year, although this did not reach statistical significance (28% vs 50%; $p = 0.28$).[30]

The use of topical nitroglycerin combined with botulinum toxin has been suggested to improve healing and symptoms in patients with chronic anal fissure.[33,34] A small prospective trial of 30 patients compared treatment with combined therapy, consisting of both nitroglycerin and botulinum toxin, to botulinum toxin alone and found improved healing rate in the combined group versus the botulinum toxin monotherapy group (60% vs 20%; $p = 0.025$).[34] Small retrospective studies evaluating botulinum toxin as second-line therapy after unsuccessful treatment with topical nitroglycerin have suggested improved symptomatic relief and avoidance of surgical sphincterotomy.[35,36]

On the basis of multiple prospective randomized clinical trials and meta-analyses, with the limitation of significant heterogeneity between studies, the available evidence supports a grade 1B.

5. Lateral internal sphincterotomy may be offered in selected pharmacologically naive patients with chronic anal fissure. Grade of recommendation: strong recommendation based on high-quality evidence, 1A.

Multiple randomized trials have confirmed the superiority of lateral internal sphincterotomy (LIS) compared with topical nitrates, calcium channel blockers, or botulinum toxin, with healing rates of 88% to 100% and with FI rates ranging from 8% to 30% based on follow-up intervals up to 6 years.[37–50] One reason for the superior results associated with LIS may be the poor compliance associated with long-term medical therapy, an observation that was confirmed by a recent Cochrane review comparing surgical and nonsurgical therapies for anal fissures.[14] Patients with duration of symptoms exceeding 1 year are less likely to respond to medical therapy.[48]

Given poor compliance and higher rates of persistent fissures with nonoperative management, and given that evidence of long-term fecal continence and quality of life are preserved in the vast majority of patients after LIS,[41,51–53] LIS can safely be offered as first-line therapy for chronic anal fissures in patients with no underlying FI. Those in whom LIS may be excluded as first-line therapy include women with prior obstetrical injuries, patients with IBD, patients who have undergone previous anorectal operations, and patients with a documented anal sphincter injury.

6. LIS is the treatment of choice for chronic anal fissures in selected patients without baseline FI. Grade of recommendation: strong recommendation based on high-quality evidence, 1A.

LIS remains the most effective surgical procedure for chronic anal fissure in patients without preoperative incontinence to gas or stool.[54] Multiple studies[8,55–58] show that LIS

Copyright © The American Society of Colon & Rectal Surgeons, Inc. Unauthorized reproduction of this article is prohibited.

is superior to uncontrolled manual anal dilation, yielding superior healing rates with lower FI. A Cochrane review of 493 patients in 7 studies found that anal dilation, compared to LIS, was associated with a nonsignificant increased rate of persistent fissure (OR 1.55; 95% CI, 0.85–2.86) and greater incidence of incontinence (OR 4.03; 95% CI, 2.04–7.96).[54] Controlled pneumatic balloon dilation has shown promise in one small series, although this treatment has not been investigated enough to serve as a standard therapy.[59] LIS has been compared to fissurectomy in one randomized trial of 62 patients, demonstrating no incontinence or recurrence in the LIS group, compared to a 6.2% rate of incontinence and 3.1% recurrence rate with fissurectomy.[60]

In 2 nonrandomized series, high-dose botulinum toxin (100 units) combined with fissurectomy led to healing in 95% of patients.[61,62] Repeated treatments may be needed to progress to complete healing. For patients with baseline preoperative FI and inadequate response to previous treatment, an advancement flap may be considered as an alternative surgical treatment, with 2 RCTs totaling 200 patients demonstrating low rates of FI between 2% and 2.5%[63,64] and other noncomparative studies demonstrating healing rates of 81% to 100%.[65,66]

7. Open and closed techniques of LIS yield similar results and either technique may be used. Grade of recommendation: strong recommendation based on high-quality evidence, 1A.

Multiple, well-designed comparative studies have demonstrated that there are no significant differences in outcomes between properly performed open and closed surgical sphincterotomies, with healing rates of 90% to 100% and 85% to 100%, respectively, and minor FI rates of 5% to 25% and 2.5% to 25%, respectively.[54,67–70] A Cochrane analysis of 5 studies including 336 patients also confirmed this finding, reporting no statistical difference with regard to fissure healing (OR 1.00, 95% CI, 0.40–2.48) and incontinence to flatus (OR 0.87; 95% CI, 0.41–1.83).[54] With regard to postoperative pain and complication rates, a randomized study of 136 patients demonstrated that open sphincterotomy was associated with significantly higher postoperative pain scores and a 4.4% delayed healing rate of the surgical site at 1-year follow-up in the open group, compared to no delayed healing in the closed group ($p = 0.08$).[71]

8. LIS tailored to the length of the fissure yields similar healing rates but decreased FI rates compared with traditional LIS extending to the dentate line. Grade of recommendation: strong recommendation based on high-quality evidence, 1B.

"Tailored" sphincterotomy, defined as sphincterotomy limited in extent to the apex of the fissure, was proposed to reduce the rate of FI after conventional LIS, the latter being defined as transecting internal sphincter muscle as far proximally as the dentate line. Three randomized trials totaling 259 patients comparing conventional versus tailored sphincterotomy showed equivalent fissure healing rates in both arms ranging from 95% to 100%.[72,73] With regard to FI, one of the studies found an increased rate of incontinence in the traditional versus tailored arm (11% vs 2%; $p = 0.04$), and the other showed a small, albeit statistically significant increase in mean incontinence scores compared to baseline in the conventional group (0.58 vs 0.16; $p = 0.02$) but not in the tailored group (0.42 vs 0.29; $p = 0.13$).[72,73] In the third study, there were slightly higher mean postoperative incontinence scores in the tailored arm, but this did not meet statistical significance (0.8 vs 0.2; $p = 0.37$).[74] Regardless of the LIS technique used, these studies demonstrated a low incidence of postoperative FI and generally minor severity of symptoms. These studies used the Wexner score to quantify FI.

A prospective study of 31 women evaluated the outcomes of tailored LIS for chronic anal fissure, of whom 55% had previous vaginal deliveries and none had preoperative FI.[75] Using endoanal ultrasound, patients were grouped on the basis of whether the LIS exceeded 25% of the total sphincter length or not. They found that mean Wexner incontinence scores[76] were significantly lower for the <25% cohort compared to the ≥25% cohort (1 vs 3; $p = 0.004$). Further supporting the tailored technique, a large retrospective study of 287 patients who underwent tailored LIS during a 30-year period found only a 1.4% rate of flatus incontinence, with no patients experiencing incontinence to stool.[77]

9. Short-term outcomes of repeat LIS or botulinum injection for recurrent anal fissure have shown good healing rates with a low risk of FI, but the data are limited and require further study. Grade of recommendation: weak recommendation based on low-quality evidence, 2C.

Only one study has evaluated the outcomes of repeat LIS for recurrent chronic anal fissures. Fifty-seven patients underwent repeat contralateral tailored LIS and showed a 98% healing rate and a 4% minor FI rate at a 12.5-year mean follow-up.[78] An alternative approach used in a study of 80 patients with recurrent anal fissure after LIS was to inject botulinum toxin into the internal anal sphincter, which resulted in a healing rate of 74% with a 10% rate of temporary flatus incontinence.[79] Larger studies with longer follow-up intervals are needed on this topic.

10. Anocutaneous flap is a safe surgical alternative for managing chronic anal fissure with a decreased risk of FI compared with LIS and comparable healing rates. Grade of recommendation: weak recommendation based on moderate-quality evidence, 2B.

For patients with chronic anal fissure who are at higher risk for FI after LIS, an alternative sphincter-preserving surgical approach is an anocutaneous (dermal V-Y or house) flap, which has been described using a variety of techniques and

Copyright © The American Society of Colon & Rectal Surgeons, Inc. Unauthorized reproduction of this article is prohibited.

which has been associated with good fissure healing rates (81%–100%) and low rates of minor FI (0%–6%).[65,80] A prospective study reported a 98% healing rate at 2 months after the construction of a flap in 51 consecutive patients, with no recurrences or changes in continence at a median follow-up of 6 months.[65] A retrospective study compared the outcomes of patients undergoing flaps (n = 50) and LIS (n = 50); at a mean follow-up of 21 months, fissure healing was achieved in 96% of patients who underwent anal advancement flap and 88% of those undergoing LIS ($p = 0.27$), with no FI reported in either group.[81] A randomized, prospective study comparing flaps (n = 50) to LIS (n = 50) showed a FI rate of 2.5% in flaps and 17% in LIS ($p = 0.01$).[63] A similar prospective study found that flaps (n = 100) had a FI rate of 2% and 17% in LIS ($p = 0.01$).[64] Neither of the 2 preceding studies assessed healing rates. Larger, prospective comparative trials are still needed to better define the role of anocutaneous flaps in the treatment of anal fissures.

11. The addition of an anocutaneous flap to botulinum toxin injection or to LIS may decrease postoperative pain and allow for primary wound healing. Grade of recommendation: weak recommendation based on low-quality evidence, 2C.

Small, noncomparative studies have demonstrated promising outcomes for patients undergoing anocutaneous flap coverage with either botulinum toxin injection or LIS. In 2 prospective studies totaling 30 patients, a combined flap with botulinum toxin injection was associated with healing rates of 86.7% to 100% at follow-up intervals ranging from 30 days up to 24 months, with resolution in pain from 76.7% to 100%, and with negligible rates of FI.[66,82] A study of 45 patients treated with a combination of fissurectomy, V-Y cutaneous advancement flap, and botulinum toxin injection demonstrated resolution of pain by postoperative day 40, 7% recurrence rate at 5 years, and 7% rate of minor temporary FI.[83]

In a retrospective study comparing the results of 30 consecutive patients who underwent tailored LIS plus V-Y perianal skin flap to 32 patients who previously underwent conventional LIS alone, the tailored LIS plus flap group experienced significantly less postoperative pain ($p < 0.001$), faster healing (80% vs 40% healed at 2 weeks; $p < 0.01$ with all healed at 3 months), and low rates of flatus incontinence (6.6% vs 28.1%; $p < 0.05$).[84] Lastly, a randomized study of 150 consecutive patients who underwent LIS (n = 50), V-Y advancement flap (n = 50), or combined LIS with V-Y advancement flap (n = 50) and who were followed for 1 year found healing rates were 84%, 48%, and 94% ($p = 0.001$), recurrence rates were 4%, 22%, and 2% ($p = 0.01$), and FI rates were 14%, 0%, and 2% ($p = 0.03$), respectively, suggesting that the addition of the flap may improve healing rates and possibly even mitigate rates of FI.[85]

Although there is one randomized trial, the majority of studies were small, retrospective, or noncomparative, and given the potential for risk and burden, the evidence supports a grade 2C recommendation.

REFERENCES

1. Gough MJ, Lewis A. The conservative treatment of fissure-in-ano. *Br J Surg.* 1983;70:175–176.
2. Hananel N, Gordon PH. Re-examination of clinical manifestations and response to therapy of fissure-in-ano. *Dis Colon Rectum.* 1997;40:229–233.
3. Lindsey I, Jones OM, Cunningham C, Mortensen NJ. Chronic anal fissure. *Br J Surg.* 2004;91:270–279.
4. Altomare DF, Binda GA, Canuti S, Landolfi V, Trompetto M, Villani RD. The management of patients with primary chronic anal fissure: a position paper. *Tech Coloproctol.* 2011;15:135–141.
5. Schouten WR, Briel JW, Auwerda JJ. Relationship between anal pressure and anodermal blood flow. The vascular pathogenesis of anal fissures. *Dis Colon Rectum.* 1994;37:664–669.
6. Stewart DB Sr, Gaertner W, Glasgow S, Migaly J, Feingold D, Steele SR. Clinical practice guideline for the management of anal fissures. *Dis Colon Rectum.* 2017;60:7–14.
7. Guyatt G, Gutterman D, Baumann MH, et al. Grading strength of recommendations and quality of evidence in clinical guidelines: report from an American College of Chest Physicians task force. *Chest.* 2006;129:174–181.
8. Jensen SL. Treatment of first episodes of acute anal fissure: prospective randomised study of lignocaine ointment versus hydrocortisone ointment or warm sitz baths plus bran. *Br Med J (Clin Res Ed).* 1986;292:1167–1169.
9. Shub HA, Salvati EP, Rubin RJ. Conservative treatment of anal fissure: an unselected, retrospective and continuous study. *Dis Colon Rectum.* 1978;21:582–583.
10. Jensen SL. Maintenance therapy with unprocessed bran in the prevention of acute anal fissure recurrence. *J R Soc Med.* 1987;80:296–298.
11. Gupta P. Randomized, controlled study comparing sitz-bath and no-sitz-bath treatments in patients with acute anal fissures. *ANZ J Surg.* 2006;76:718–721.
12. Emile SH, Elgendy H, Elfeki H, et al. Does the duration of symptoms of anal fissure impact its response to conservative treatment? A prospective cohort study. *Int J Surg.* 2017;44:64–70.
13. Berry SM, Barish CF, Bhandari R, et al. Nitroglycerin 0.4% ointment vs placebo in the treatment of pain resulting from chronic anal fissure: a randomized, double-blind, placebo-controlled study. *BMC Gastroenterol.* 2013;13:106.
14. Nelson RL, Thomas K, Morgan J, Jones A. Non surgical therapy for anal fissure. *Cochrane Database Syst Rev.* 2012:CD003431.
15. Scholefield JH, Bock JU, Marla B, et al. A dose finding study with 0.1%, 0.2%, and 0.4% glyceryl trinitrate ointment in patients with chronic anal fissures. *Gut.* 2003;52:264–269.
16. Ala S, Enayatifard R, Alvandipour M, Qobadighadikolaei R. Comparison of captopril (0.5%) cream with diltiazem (2%) cream for chronic anal fissure: a prospective randomized double-blind two-centre clinical trial. *Colorectal Dis.* 2016;18:510–516.

Copyright © The American Society of Colon & Rectal Surgeons, Inc. Unauthorized reproduction of this article is prohibited.

17. Nelson RL, Manuel D, Gumienny C, et al. A systematic review and meta-analysis of the treatment of anal fissure. *Tech Coloproctol.* 2017;21:605–625.
18. Bailey HR, Beck DE, Billingham RP, et al; Fissure Study Group. A study to determine the nitroglycerin ointment dose and dosing interval that best promote the healing of chronic anal fissures. *Dis Colon Rectum.* 2002;45:1192–1199.
19. Sanei B, Mahmoodieh M, Masoudpour H. Comparison of topical glyceryl trinitrate with diltiazem ointment for the treatment of chronic anal fissure: a randomized clinical trial. *Acta Chir Belg.* 2009;109:727–730.
20. Sajid MS, Whitehouse PA, Sains P, Baig MK. Systematic review of the use of topical diltiazem compared with glyceryltrinitrate for the nonoperative management of chronic anal fissure. *Colorectal Dis.* 2013;15:19–26.
21. Nevins EJ, Kanakala V. Topical diltiazem and glyceryl-trinitrate for chronic anal fissure: a meta-analysis of randomised controlled trials. *Turk J Surg.* 2020;36:347–352.
22. Golfam F, Golfam P, Golfam B, Pahlevani P. Comparison of topical nifedipine with oral nifedipine for treatment of anal fissure: a randomized controlled trial. *Iran Red Crescent Med J.* 2014;16:e13592.
23. Agrawal V, Kaushal G, Gupta R. Randomized controlled pilot trial of nifedipine as oral therapy vs. topical application in the treatment of fissure-in-ano. *Am J Surg.* 2013;206:748–751.
24. Sahebally SM, Ahmed K, Cerneveciute R, Iqbal A, Walsh SR, Joyce MR. Oral versus topical calcium channel blockers for chronic anal fissure-a systematic review and meta-analysis of randomized controlled trials. *Int J Surg.* 2017;44:87–93.
25. Bhama AR, Zoccali MB, Chapman BC, et al. Practice variations in chemodenervation for anal fissure among American Society of Colon and Rectal Surgeons members. *Dis Colon Rectum.* 2021;64:1167–1171.
26. Bobkiewicz A, Francuzik W, Krokowicz L, et al. Botulinum toxin injection for treatment of chronic anal fissure: is there any dose-dependent efficiency? A meta-analysis. *World J Surg.* 2016;40:3064–3072.
27. Lin JX, Krishna S, Su'a B, Hill AG. Optimal dosing of botulinum toxin for treatment of chronic anal fissure: a systematic review and meta-analysis. *Dis Colon Rectum.* 2016;59:886–894.
28. Kyriakakis R, Kelly-Schuette K, Hoedema R, Luchtefeld M, Ogilvie J. What predicts successful nonoperative management with botulinum toxin for anal fissure? *Am J Surg.* 2020;219:442–444.
29. Lysy J, Israeli E, Levy S, Rozentzweig G, Strauss-Liviatan N, Goldin E. Long-term results of "chemical sphincterotomy" for chronic anal fissure: a prospective study. *Dis Colon Rectum.* 2006;49:858–864.
30. Berkel AE, Rosman C, Koop R, van Duijvendijk P, van der Palen J, Klaase JM. Isosorbide dinitrate ointment vs botulinum toxin A (Dysport) as the primary treatment for chronic anal fissure: a randomized multicentre study. *Colorectal Dis.* 2014;16:O360–O366.
31. Samim M, Twigt B, Stoker L, Pronk A. Topical diltiazem cream versus botulinum toxin a for the treatment of chronic anal fissure: a double-blind randomized clinical trial. *Ann Surg.* 2012;255:18–22.
32. Sajid MS, Vijaynagar B, Desai M, Cheek E, Baig MK. Botulinum toxin vs glyceryltrinitrate for the medical management of chronic anal fissure: a meta-analysis. *Colorectal Dis.* 2008;10:541–546.
33. Madalinski MH, Slawek J, Zbytek B, et al. Topical nitrates and the higher doses of botulinum toxin for chronic anal fissure. *Hepatogastroenterology.* 2001;48:977–979.
34. Lysy J, Israelit-Yatzkan Y, Sestiery-Ittah M, Weksler-Zangen S, Keret D, Goldin E. Topical nitrates potentiate the effect of botulinum toxin in the treatment of patients with refractory anal fissure. *Gut.* 2001;48:221–224.
35. Lindsey I, Jones OM, Cunningham C, George BD, Mortensen NJ. Botulinum toxin as second-line therapy for chronic anal fissure failing 0.2 percent glyceryl trinitrate. *Dis Colon Rectum.* 2003;46:361–366.
36. Whatley JZ, Tang SJ, Glover PH, et al. Management of complicated chronic anal fissures with high-dose circumferential chemodenervation (HDCC) of the internal anal sphincter. *Int J Surg.* 2015;24:24–26.
37. Richard CS, Gregoire R, Plewes EA, et al. Internal sphincterotomy is superior to topical nitroglycerin in the treatment of chronic anal fissure: results of a randomized, controlled trial by the Canadian Colorectal Surgical Trials Group. *Dis Colon Rectum.* 2000;43:1048–1057.
38. Arroyo A, Pérez F, Serrano P, Candela F, Lacueva J, Calpena R. Surgical versus chemical (botulinum toxin) sphincterotomy for chronic anal fissure: long-term results of a prospective randomized clinical and manometric study. *Am J Surg.* 2005;189:429–434.
39. Iswariah H, Stephens J, Rieger N, Rodda D, Hewett P. Randomized prospective controlled trial of lateral internal sphincterotomy versus injection of botulinum toxin for the treatment of idiopathic fissure in ano. *ANZ J Surg.* 2005;75:553–555.
40. Katsinelos P, Papaziogas B, Koutelidakis I, et al. Topical 0.5% nifedipine vs. lateral internal sphincterotomy for the treatment of chronic anal fissure: long-term follow-up. *Int J Colorectal Dis.* 2006;21:179–183.
41. Brown CJ, Dubreuil D, Santoro L, Liu M, O'Connor BI, McLeod RS. Lateral internal sphincterotomy is superior to topical nitroglycerin for healing chronic anal fissure and does not compromise long-term fecal continence: six-year follow-up of a multicenter, randomized, controlled trial. *Dis Colon Rectum.* 2007;50:442–448.
42. Davies I, Dafydd L, Davies L, Beynon J. Long term outcomes after lateral anal sphincterotomy for anal fissure: a retrospective cohort study. *Surg Today.* 2014;44:1032–1039.
43. de Rosa M, Cestaro G, Vitiello C, Massa S, Gentile M. Conservative versus surgical treatment for chronic anal idiopathic fissure: a prospective randomized trial. *Updates Surg.* 2013;65:197–200.
44. Sileri P, Stolfi VM, Franceschilli L, et al. Conservative and surgical treatment of chronic anal fissure: prospective longer term results. *J Gastrointest Surg.* 2010;14:773–780.
45. Valizadeh N, Jalaly NY, Hassanzadeh M, et al. Botulinum toxin injection versus lateral internal sphincterotomy for the treatment of chronic anal fissure: randomized prospective controlled trial. *Langenbecks Arch Surg.* 2012;397:1093–1098.
46. Menteş BB, Irkörücü O, Akin M, Leventoğlu S, Tatlicioğlu E. Comparison of botulinum toxin injection and lateral internal sphincterotomy for the treatment of chronic anal fissure. *Dis Colon Rectum.* 2003;46:232–237.
47. Nasr M, Ezzat H, Elsebae M. Botulinum toxin injection versus lateral internal sphincterotomy in the treatment of chronic

Copyright © The American Society of Colon & Rectal Surgeons, Inc. Unauthorized reproduction of this article is prohibited.

anal fissure: a randomized controlled trial. *World J Surg.* 2010;34:2730–2734.
48. Gandomkar H, Zeinoddini A, Heidari R, Amoli HA. Partial lateral internal sphincterotomy versus combined botulinum toxin A injection and topical diltiazem in the treatment of chronic anal fissure: a randomized clinical trial. *Dis Colon Rectum.* 2015;58:228–234.
49. Acar T, Acar N, Güngör F, et al. Comparative efficacy of medical treatment versus surgical sphincterotomy in the treatment of chronic anal fissure. *Niger J Clin Pract.* 2020;23:539–544.
50. Chen HL, Woo XB, Wang HS, et al. Botulinum toxin injection versus lateral internal sphincterotomy for chronic anal fissure: a meta-analysis of randomized control trials. *Tech Coloproctol.* 2014;18:693–698.
51. Hyman N. Incontinence after lateral internal sphincterotomy: a prospective study and quality of life assessment. *Dis Colon Rectum.* 2004;47:35–38.
52. Ortiz H, Marzo J, Armendariz P, De Miguel M. Quality of life assessment in patients with chronic anal fissure after lateral internal sphincterotomy. *Br J Surg.* 2005;92:881–885.
53. Menteş BB, Tezcaner T, Yilmaz U, Leventoğlu S, Oguz M. Results of lateral internal sphincterotomy for chronic anal fissure with particular reference to quality of life. *Dis Colon Rectum.* 2006;49:1045–1051.
54. Nelson RL, Chattopadhyay A, Brooks W, Platt I, Paavana T, Earl S. Operative procedures for fissure in ano. *Cochrane Database Syst Rev.* 2011:CD002199.
55. Saad AM, Omer A. Surgical treatment of chronic fissure-in-ano: a prospective randomised study. *East Afr Med J.* 1992;69:613–615.
56. Olsen J, Mortensen PE, Krogh Petersen I, Christiansen J. Anal sphincter function after treatment of fissure-in-ano by lateral subcutaneous sphincterotomy versus anal dilatation. A randomized study. *Int J Colorectal Dis.* 1987;2:155–157.
57. Weaver RM, Ambrose NS, Alexander-Williams J, Keighley MR. Manual dilatation of the anus vs. lateral subcutaneous sphincterotomy in the treatment of chronic fissure-in-ano. Results of a prospective, randomized, clinical trial. *Dis Colon Rectum.* 1987;30:420–423.
58. Ram E, Vishne T, Lerner I, Dreznik Z. Anal dilatation versus left lateral sphincterotomy for chronic anal fissure: a prospective randomized study [published online ahead of print December 3, 2007]. *Tech Coloproctol.* doi:10.1007/s10151-007-0373-7.
59. Renzi A, Izzo D, Di Sarno G, et al. Clinical, manometric, and ultrasonographic results of pneumatic balloon dilatation vs. lateral internal sphincterotomy for chronic anal fissure: a prospective, randomized, controlled trial. *Dis Colon Rectum.* 2008;51:121–127.
60. Mousavi SR, Sharifi M, Mehdikhah Z. A comparison between the results of fissurectomy and lateral internal sphincterotomy in the surgical management of chronic anal fissure. *J Gastrointest Surg.* 2009;13:1279–1282.
61. Barnes TG, Zafrani Z, Abdelrazeq AS. Fissurectomy combined with high-dose botulinum toxin is a safe and effective treatment for chronic anal fissure and a promising alternative to surgical sphincterotomy. *Dis Colon Rectum.* 2015;58:967–973.
62. Farouk R. Sphincter-preserving therapy for treating a chronic anal fissure: long-term outcomes. *Ann Coloproctol.* 2014;30:132–134.
63. Shaikh AR, Rao AMK, Muneer A. A comparative study of the results of the anal fissurectomy and lateral internal sphincterotomy for chronic anal fissure. *Pak J Med Sci.* 2012;28:112–115.
64. Mirani SH, Kumar D, Ahmad A. Comparison of outcome of lateral sphincterotomy with anal advancement flap in patients of anal fissure. *Pak J Med Health Sci.* 2021;15:368–369.
65. Giordano P, Gravante G, Grondona P, Ruggiero B, Porrett T, Lunniss PJ. Simple cutaneous advancement flap anoplasty for resistant chronic anal fissure: a prospective study. *World J Surg.* 2009;33:1058–1063.
66. Patti R, Guercio G, Territo V, Aiello P, Angelo GL, Di Vita G. Advancement flap in the management of chronic anal fissure: a prospective study. *Updates Surg.* 2012;64:101–106.
67. Boulos PB, Araujo JG. Adequate internal sphincterotomy for chronic anal fissure: subcutaneous or open technique? *Br J Surg.* 1984;71:360–362.
68. Kortbeek JB, Langevin JM, Khoo RE, Heine JA. Chronic fissure-in-ano: a randomized study comparing open and subcutaneous lateral internal sphincterotomy. *Dis Colon Rectum.* 1992;35:835–837.
69. Arroyo A, Pérez F, Serrano P, Candela F, Calpena R. Open versus closed lateral sphincterotomy performed as an outpatient procedure under local anesthesia for chronic anal fissure: prospective randomized study of clinical and manometric long-term results. *J Am Coll Surg.* 2004;199:361–367.
70. Wiley M, Day P, Rieger N, Stephens J, Moore J. Open vs. closed lateral internal sphincterotomy for idiopathic fissure-in-ano: a prospective, randomized, controlled trial. *Dis Colon Rectum.* 2004;47:847–852.
71. Gupta V, Rodrigues G, Prabhu R, Ravi C. Open versus closed lateral internal anal sphincterotomy in the management of chronic anal fissures: a prospective randomized study. *Asian J Surg.* 2014;37:178–183.
72. Elsebae MM. A study of fecal incontinence in patients with chronic anal fissure: prospective, randomized, controlled trial of the extent of internal anal sphincter division during lateral sphincterotomy. *World J Surg.* 2007;31:2052–2057.
73. Menteş BB, Ege B, Leventoglu S, Oguz M, Karadag A. Extent of lateral internal sphincterotomy: up to the dentate line or up to the fissure apex? *Dis Colon Rectum.* 2005;48:365–370.
74. Ho KS, Ho YH. Randomized clinical trial comparing oral nifedipine with lateral anal sphincterotomy and tailored sphincterotomy in the treatment of chronic anal fissure. *Br J Surg.* 2005;92:403–408.
75. Murad-Regadas SM, Fernandes GO, Regadas FS, et al. How much of the internal sphincter may be divided during lateral sphincterotomy for chronic anal fissure in women? Morphologic and functional evaluation after sphincterotomy. *Dis Colon Rectum.* 2013;56:645–651.
76. Jorge JM, Wexner SD. Etiology and management of fecal incontinence. *Dis Colon Rectum.* 1993;36:77–97.
77. Littlejohn DR, Newstead GL. Tailored lateral sphincterotomy for anal fissure. *Dis Colon Rectum.* 1997;40:1439–1442.
78. Liang J, Church JM. Lateral internal sphincterotomy for surgically recurrent chronic anal fissure. *Am J Surg.* 2015;210:715–719.
79. Brisinda G, Cadeddu F, Brandara F, et al. Botulinum toxin for recurrent anal fissure following lateral internal sphincterotomy. *Br J Surg.* 2008;95:774–778.
80. Kennedy ML, Sowter S, Nguyen H, Lubowski DZ. Glyceryl trinitrate ointment for the treatment of chronic anal

Copyright © The American Society of Colon & Rectal Surgeons, Inc. Unauthorized reproduction of this article is prohibited.

fissure: results of a placebo-controlled trial and long-term follow-up. *Dis Colon Rectum.* 1999;42:1000–1006.
81. Patel SD, Oxenham T, Praveen BV. Medium-term results of anal advancement flap compared with lateral sphincterotomy for the treatment of anal fissure. *Int J Colorectal Dis.* 2011;26:1211–1214.
82. Halahakoon VC, Pitt JP. Anal advancement flap and botulinum toxin A (BT) for chronic anal fissure (CAF). *Int J Colorectal Dis.* 2014;29:1175–1177.
83. D'Orazio B, Geraci G, Martorana G, Sciumé C, Corbo G, Di Vita G. Fisurectomy and anoplasty with botulinum toxin injection in patients with chronic anal posterior fissure with hypertonia: a long-term evaluation. *Updates Surg.* 2021;73:1575–1581.
84. Theodoropoulos GE, Spiropoulos V, Bramis K, Plastiras A, Zografos G. Dermal flap advancement combined with conservative sphincterotomy in the treatment of chronic anal fissure. *Am Surg.* 2015;81:133–142.
85. Magdy A, El Nakeeb A, Fouda Y, Youssef M, Farid M. Comparative study of conventional lateral internal sphincterotomy, V-Y anoplasty, and tailored lateral internal sphincterotomy with V-Y anoplasty in the treatment of chronic anal fissure. *J Gastrointest Surg.* 2012;16:1955–1962.

Copyright © The American Society of Colon & Rectal Surgeons, Inc. Unauthorized reproduction of this article is prohibited.